



Printed in Nigeria

CRYPTORCHIDISM AND HYPERTHERMIA-INDUCED TESTICULAR INJURY IN ADULT MALE RATS; INTERVENTION OF ALPHA TOCOPHEROL

Adunmo GO¹., Lawal AZ¹ ., Oyewopo AO³., Oyewopo CI⁴., Stephen DA⁵., Akindehin OA³., Adunfe OO⁶., Adeleke OS⁷., Hamzat FO⁸., Ashamu EA⁹

¹Department of Medical Laboratory Science, Faculty of Basic Medical Sciences, College of Health Sciences, University of Ilorin, Ilorin, Nigeria

²Department of Medical Biochemistry, Faculty of Basic Medical Sciences, College of Health Sciences, University of Ilorin, Ilorin, Nigeria

³Department of Anatomy, Faculty of Basic Medical Sciences, Colleges of Health Sciences, University of Ilorin, Kwara State, Nigeria.

⁴Department of Anaesthesia, University of Ilorin, Teaching Hospital (UITH), Ilorin, Kwara State.

⁵Department of Environmental Health Science, Faculty of Basic Medical and Health Sciences, Thomas Adewunmi University, Oko, Nigeria.

⁶Anatomy Unit, Department of Medical Laboratory Sciences, Colleges of Basic Medical and Health Sciences, Fountain University, Osogbo, Nigeria

⁷Department of Anatomy, Faculty of Basic Medical Sciences, College of Health Sciences, Osun State University, Oshogbo, Nigeria.

⁸Department of Human Anatomy, Faculty of Health Sciences, All-Hikmah University, Ilorin, Nigeria

⁹Department of Anatomy, Faculty of Basic Medical Sciences, Colleges of Health Sciences, Ladoke Akintola University Technology, Ogbomoso, Oyo State, Nigeria.

Corresponding Author: Prof.. Oyewopo AO, E-mail: wolesake@yahoo.com.

MS/No BKM/2022/012© 2022 Society for Experimental Biology of Nigeria

Corresponding author's email: wolesake@yahoo.com

ABSTRACT

The objective of this study is to determine the effects of cryptorchidism and hyperthermia on the testicular cytoarchitecture of adult male rats, quality and quantity of semen and the level of oxidative stress in the testes before and after intervention of Alpha-tocopherol (Vitamin E). Twenty-four (24) adult Wistar rats were used for this experiment and they were divided into seven groups (n=4). Experimental

cryptorchidism was carried out in some animals while others were subjected to hyperthermia from two sources (hot oven and light bulb) for 28 days; followed by intervention of 100mg/kg alpha-tocopherol for fourteen (14) days. All animals were then euthanized under anaesthesia. The testes were excised and fixed and processed using haematoxylin and eosin technique. Plasma was assayed for glutathione, superoxide dismutase (SOD) and malondialdehyde (MDA). Cryptorchidism and hyperthermia caused in cycto-architectural distortion in the testicular structures of exposed animals and significant reductions in caudal epididymal sperm count and motility, morphology and life and death ratio. Plasma SOD and GLU levels also reduced significantly in exposed animals while MDA levels increased significantly, indicating peroxidation of testicular tissue. Alpha-tocopherol due to its anti-oxidative properties impeded lipoperoxidation of the membrane, conserving cell union and increasing the amount of germ cells in the seminiferous epithelium. At doses and durations tested, alpha-tocopherol (α T) reverted to a significant extent the effects of cryptorchidism and hyperthermia by reducing apoptosis in germ cells, promoting cell survival and reducing histological alterations to the seminiferous epithelium.

Keywords: Cryptorchidism, hyperthermia and Alpha-tocopherol

INTRODUCTION

The testes function in production of the male gametes or spermatozoa and male sexual hormone, (hence referred to as double glands) which stimulates the accessory male sexual organs and causes the development of the male sex characteristics (Mescher, 2010; Lutz, 2009). In most mammals, the temperature around the testicular region is lower than the core body temperature. In man, scrotal temperature is 2-3⁰C lower than rectal temperature and the optimum temperature. Impaired testicular thermoregulation is commonly implicated in abnormal spermatogenesis and impaired sperm function in animals and humans, with outcomes ranging from subclinical infertility to sterility (Thundathi *et al.*, 2012). Oyewopo and Togun in 2005 reported that a small increase in the temperature of the testis does not destroy the germinal epithelium; however, it reduces testis weight and sperm production and brings a greater incidence of morphologically abnormal spermatids and spermatozoa (Oyewopo and Togun, 2005; Bedford, 1991). Occupational exposure to high temperatures adversely affects testicular function causing partial or complete spermatogenic arrest, also causes deterioration in sperm morphology and impairs motility. This leads to oligoasthenoteratozoospermia (OAT) and azoospermia (Dada *et al.*, 2001). Cryptorchidism (undescended testes); the absence of one or both testes from the scrotum happens to be the most common birth defect of the male genitalia, which if persists could result in reduced fertility and

increased risk of testicular germ cell tumors (Wood and Elder, 2009). Cryptorchidism has been implicated to cause oxidative stress in animals that the process was performed on, it was reported that Cryptorchid rats had lower testicular weight, sperm count, germ cell count, testicular superoxide dismutase (SOD) concentration, testicular total protein and higher testicular malondialdehyde (MDA) concentration compared to animals in control group (Ayobami *et al.*, 2013; Dutta *et al.*, 2013). Alpha-Tocopherol (α T) is an important antioxidant that localizes to cell membranes. The primary function of vitamin E is as an antioxidant; because it helps reduce oxidation of lipid membranes and the unsaturated fatty acids and prevents the breakdown of other nutrients by oxygen. This protective, nutritional antioxidant function is also performed and enhanced by other antioxidants, such as vitamin C, beta-carotene, glutathione (L-cysteine), and the mineral selenium (Laila and Sahar 2009; Aybek *et al.*, 2008; Traber and Kayden 1987). A significant reduction of lipoperoxidation was observed in the cryptorchid group treated with α -Tocopherol compared to the untreated cryptorchid group, at long term, an increase in the area and maturation of the seminiferous epithelium, a decrease in apoptosis and histological alterations and an increase in fertility was observed in animals treated with Alpha-Tocopherol (Saalu *et al.*, 2014; Rosa *et al.*, 2011).

The broad aim of this study investigates the protective properties of alpha tocopherol (vitamin

E) on cryptorchidic and heat (hyperthermia) induced testicular injury.

MATERIALS AND METHODS

The experiment was performed in conformity with the Rules and Guidelines of the Animal Ethics Committee of University of Ilorin. The experiments were conducted at the Department of Anatomy, College of Health Science, University of Ilorin.

Animals

Twenty-four (24) male Wistar rats (150-210g) were purchased from Banky livestock company, Oke-Ose, Ilorin, Kwara State. The animals were kept in the animal house of the Faculty of Clinical Science, University of Ilorin, under light and dark cycle at room temperature. Proper aeration maintained by the use of wire gauze wooden cage. The rats were fed on growers' feed from Bendel feeds Nigeria Limited, Ilorin, and distilled water throughout the duration of the experiment. The rats were arranged randomly into groups A-F, kept in different compartments of the cage. The rats were left under the above stated condition for two weeks so as to acclimatize with the condition of their new environment.

Grouping of animals

Group A- (n=4) control animals; these experimental animals were given pelleted feed and tap water ad libitum throughout the period of the experiment;

Group B- (n=4) experimental cryptorchidism was carried out this group;

Group C- (n=4) experimental cryptorchidism was carried out and then 100mg alpha tocopherol for 14days;

Group D- (n=4) animals were exposed to heat from hot oven for 28 days;

Group E- (n=4) animals were exposed to heat from hot oven for 28 days then 100mg/kg vitamin E for 14days;

group F- (n=4) animals were exposed to heat from light bulb for 28 days, group G- animals were exposed to heat from light bulb for 28 days then 100mg/kg vitamin E for 14days.

Animal sacrifice and Tissue collection

At the end of the substance administration, the rats were sacrificed 24hrs after the last day of the

exposure using ketamine (0.2ml). The animals were pinned on the dissecting board. Dissection was done on the anterior abdominal wall (thoraco-abdominal sagittal incision) using the necessary surgical equipment/instruments. Blood was first collected via the apex of the heart with a hypodermic syringe, and the blood was centrifuged, the epididymis was also excised and placed in normal saline for semen analysis. The testis was removed and then fixed Bouin's fluid.

Semen analysis

The testes from each rat were carefully exposed and removed. They were trimmed free of the epididymis and adjoining tissues. Epididymal sperm concentration: Spermatozoa in the right epididymis were counted by a modified method of Yokoi and Mayi, (2003). Briefly, the epididymis was minced with anatomic scissors' in 5mL physiologic saline, placed in a rocker for 10 minutes, and allowed to incubate at room temperature for 2 minutes. After incubation, the supernatant fluid was diluted 1:100 with solution containing 5 g sodium bicarbonate and 1mL formalin (35%). Total sperm number was determined by using the new improved Neuber's counting chamber (haemocytometer). Approximately 10 μ L of the diluted sperm suspension was transferred to each counting chamber of the haemocytometer and was allowed to stand for 5 minutes. This chamber was then placed under a binocular light microscope using an adjustable light source. The ruled part of the chamber was then focused and the number of spermatozoa counted in five 16-celled squares. The sperm concentration was the calculated multiplied by 5 and expressed as [X] x 10⁶ /ml, where [X] is the number of spermatozoa in a 16-celled square (Oyewopo *et al.*, 2010).

Sperm progressive motility: This was evaluated by an earlier method by Sonmez *et al.*, (2005). The fluid obtained from the left cauda epididymis with a pipette was diluted to 0.5 mL with Tris buffer solution. A slide was placed on light microscope with heater table, an aliquot of this solution was on the slide, and percentage motility was evaluated visually at a magnification of x 400. Motility estimates were performed from three different fields in each sample. The mean of the three estimations was used as the final motility score. Samples for motility evaluation were stored

at 35⁰c. Sperm morphology: The sperm cells were evaluated with the aid of light microscope at x 400 magnification. Caudal sperm were taken from the original dilution for motility and diluted 1:20 with 10% neutral buffered formalin (Sigma-Aldrich, Oakville, ON, Canada). Five hundred sperm from the sample were scored for morphological abnormalities (Atessahin *et al.*, 2006). Briefly, in wet preparations using phase-contrast optics, spermatozoa were categorized. In this study a spermatozoon was considered abnormal morphologically if it had one or more of the following features: rudimentary tail, round head and detached head and was expressed as a percentage of morphologically normal sperm (Oyewopo *et al.*, 2010).

Estimation of Lipid peroxidation (Malondialdehyde)

Lipid peroxidation in the testicular tissue was estimated calorimetrically by thiobarbituric acid reactive substances TBARS method of Buege and Aust (1978). A principle component of TBARS being malondialdehyde (MDA), a product of lipid peroxidation. In brief, 0.1 ml of tissue homogenate (Tris-HCl buffer, pH 7.5) was treated with 2 ml of (1:1:1 ratio) TBA-TCA-HCl reagent (thiobarbituric acid 0.37%, 0.25 N HCl and 1 5% TCA) and placed in water bath for 1 5 min, cooled. The absorbance of clear supernatant was measured against reference blank at 535nm. Concentration was calculated using the molar absorptivity of malondialdehyde which is 1 .56 x1 05 M-1 cm-1 and expressed as nmol/mg protein (Oyewopo *et al.*, 2010).

Estimation of Glutathione level

Total GSH was estimated in various tissues by the method of Sedlak and Lindsay. Briefly, 5% tissue homogenates were prepared in 20 mM EDTA, pH 4.7, and 100 µl of the homogenate or pure GSH was added to 0.2 M Tris-EDTA buffer (1.0 ml, pH 8.2) and 20 mM EDTA, pH 4.7 (0.9 ml) followed by 20 µl of Ellman's reagent (10 mmol/l DTNB in methanol). After 30 min of incubation at room temperature, absorbance was read at 412 nm in a Beckman DU-640 spectrophotometer. Samples were centrifuged before the absorbance of the supernatants was measured (Sedlak and Lindsay, 1968).

Estimation of Superoxide dismutase (SOD) level

Testicular tissues were transferred into 5ml ice-cold sucrose solution (0.25M) and homogenized. The homogenates were further centrifuged at 3000 rpm for 15 min to obtain the supernatant, which was then aspirated with Pasteur pipette into sample bottle, stored overnight at 4°C before being used for assays. Tissue activities of superoxide dismutase (SOD) were determined by the method of Marklund and Marklund, (1974).

Statistical Analysis

Data collected were analysed using Microsoft Excel and one-way analysis of variance (ANOVA) followed by Tukey's multiple comparison test (HSD) with the aid of SPSS V20. Data were presented as means ± SEM (standard error of mean) P value less than 0.05 (p<0.05) was considered statistically significant.

RESULTS

Histological Observation

The micrograph from control group (group A) showed normal population of germinal epithelium, intact structure and arrangement of seminiferous tubules, presence of leydig cell, and well vascularized. Micrograph from group B (cryptorchidic animals) showed degeneration of spermatogenic cells and absence of spermatozoa in the lumen. Micrograph from Group C (cryptorchidic animals that were given alpha tocopherol) showed regeneration of spermatogenic cells and evidence of spermatogenesis due to presence of spermatozoa in the lumen. Micrograph from animals exposed to heat from hot oven (Group D), showed degeneration of basement membrane and clustering of spermatogonia cells, but Regeneration of spermatogenic cells and normal spermatogenesis was evident in animals exposed to heat from hot oven followed by alpha-tocopherol (group E). Micrograph of animals exposed to heat from light bulb (Group D), showed distorted interstitium and cellular hyperplasia, which was reversed in animals that was given alpha-tocopherol.

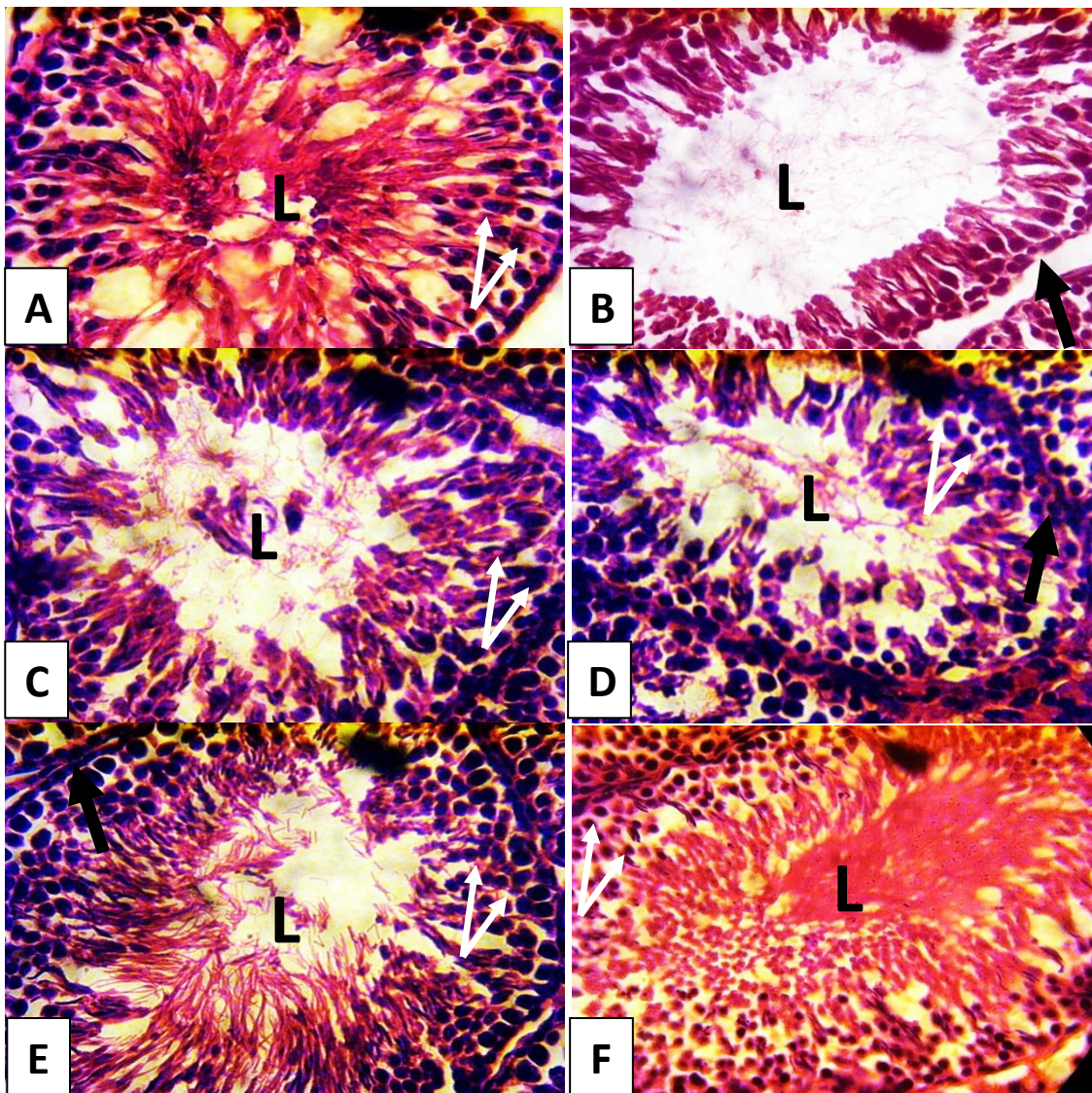
Semen Analysis

Table 1: percentage sperm count, sperm motility, life and ratio and sperm morphology across all groups.

GROUPS	SC (*10 ⁶ %)	SM (%)	L/D (%)	MORPH (%)
A	64±8.08	83±1.8	89±8.59	89±5.79
B	19±6.2*	34±6.93*	44±7.13*	34±8.04*
C	57±2.04	54±2.62*	72±5.68*	82±6.21
D	19±3.7*	46±4.7*	39±6.16*	45±2.39*
E	48±3.2*	73±1.99*	75±9.9*	76±2.5*
F	18±2.6*	48±9.42*	43±7.91*	39±5.8*
G	40±6.5*	77±5.3	72±7.98*	77±8.35*

Data were presented in mean±SEM.

*(P<0.05) statistical significant difference compared to control (group A).



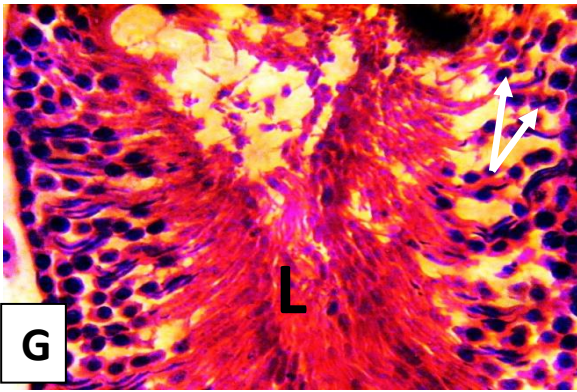


Plate (A-G): photomicrographs showing the cyto-architecture of the testes across all experimental groups. Stain- Haematoxylin and Eosin (H & E). Mag- 400.

A- Control, B- cryptorchidism, C- crypt + vit E, D- hot oven, E- hot oven + vit E, F- light bulb, G- light bulb + vit E.

L-Lumen, **White arrows**- Spermatogenic cells, **Black arrow**- Basement membrane.

Biochemical analysis

Table 2: malondialdehyde (MDA), glutathione (GLU) and superoxide dismutase (SOD) levels across all groups.

GROUPS	MDA ($\mu\text{mol/L}$)	GLU (IU/L)	SOD ($\mu\text{mol/L}$)
Control (a)	3.57 \pm 0.23	6.5 \pm 0.32	5.9 \pm 0.40
Cryptorchidism (b)	4.97 \pm 0.33	4.4 \pm 0.42*	7.27 \pm 0.18*
Crypt + vit e (c)	3.2 \pm 0.15	5.2 \pm 0.55	3.87 \pm 0.19*
Hot oven (d)	5.27 \pm 0.49*	4.07 \pm 0.29*	7.6 \pm 0.32*
Hot oven + vit e (e)	3.9 \pm 0.26	5.47 \pm 0.29	3.57 \pm 0.23*
Light bulb (f)	5.9 \pm 0.47*	3.96 \pm 0.33*	8.1 \pm 0.19*
Light bulb	5.9 \pm 0.47*	5.5 \pm 0.29	3.97 \pm 0.33*

Data were presented in mean \pm SEM. *(P<0.05) statistical significant difference compared to control (group A).

DISCUSSION

Cryptorchidism and hyperthermia caused desquamation and degeneration of germ cells which might be due to the destabilization of Sertoli cell membranes caused by lipoperoxidation, irregular shape of the seminiferous tubule, and degeneration of the interstitial tissues; this was in accordance to the report of Dutta *et al.*, in 2013; Oyewopo and Togun in 2005 and Lee and Coughlin, in 2001. In cryptorchidic and hyperthermic animals exposed to alpha tocopherol (α T), lipoperoxidation of the membrane was impeded, conserving cell union and increasing the amount of germ cells in the seminiferous epithelium (Shikone *et al.*, 1994).

The reduction in sperm parameters analysed as seen in figures 4.2 to 4.6 (i.e. sperm counts, motility, life and death ratio and morphology) in both cryptorchidic and heat treated animals might be due oxidative stress action that cryptorchidism and hyperthermia cause to testicular tissues. Oyewopo & Togun in 2005 and Lee & Coughlin in 2001 also reported a significant reduction in sperm parameters of cryptorchidic and heat treated animals. But the effects of cryptorchidism and hyperthermia (heat) was reversed in animals treated with alpha tocopherol (Vitamin E) by not only returning sperm parameters to normalcy but also enhance the rate of spermatogenesis in the animals. My finding was corroborated by works of Saalu *et al.*, in 2014 and Rosa *et al.*, in 2011. Cryptorchidism and hyperthermia cause a decrease in antioxidant enzyme activity or an increase in the production of ROS, (i.e.

superoxide anion, hydroxyl radical, nitric oxide and hydrogen peroxide) which stimulates lipoperoxidation which results in increase in malondialdehyde and reduced glutathione and superoxide dismutase levels in exposed animals. The work of Saalu *et al.*, 2014; Rosa *et al.*, 2011; Ishii *et al.*, 2005 corroborate my findings. However administration of alpha tocopherol to the treated groups showed increase in cell's endogenous antioxidant defence system, inhibiting ROS production and impede lipoperoxidation (as seen in figures 4.8 to 4.10). This result was corroborated by work of Saalu *et al.*, 2014; Ayobami *et al.*, 2013; Rosa *et al.*, 2011 and Laila and Sahar in 2009.

CONCLUSION

Cryptorchidism and hyperthermia resulted in oxidative stress in exposed animals which is evident in distortion seen in the histological slides, reduced sperm parameters and antioxidant activities. This work showed that α T reduced apoptosis in germ cells, promoting cell survival and reducing histological alterations to the seminiferous epithelium.

REFERENCES

- Aybek H., Aybek Z., Rota S., Sen N. and Akbulut M., (2008). The effects of diabetes mellitus, age, and vitamin E on testicular oxidative stress. *Fertil Steril.*, 90(3): 755-760.
- Ayobami O. A., Hameed A. A., and Isiaka A. A. (2013). Effects of methanolic extract of moringa oleifera leaves on semen and

- Biochemical parameters in cryptorchid rats. *Afr J Tradit Complement Altern Med.* (2013) 10(5):230-235.
- Bedford J.M. (1991). Effects of elevated temperature on the epididymis and testis: experimental studies. *Adv Exp Med Biol.* 1991; 286:19-32.
- Dada R., Gupta, N.P., Kucheria K. (2001). Deterioration of Sperm Morphology in Men Exposed To High Temperature. *J Anat. Soc. India* 50(2) 107-111 (2001).
- Dutta S., Joshi K.R., Sengupta P., Bhattacharya K. (2013). Unilateral and bilateral cryptorchidism and its effect on the testicular morphology, histology, accessory sex organs, and sperm count in laboratory mice. *J Hum Reprod Sci.* 2013 Apr; 6 (2):106- 10.
- Ishii T., Matsuki S., Iuchi Y., Okada F., Toyosaki S., Tomita Y., Ikeda Y., Fujii J., (2005). Accelerated impairment of spermatogenic cells in SOD1-knockout mice under heat stress. *Free Radic. Res.* 39, 697–705.
- Laila Sabik M.E. and Sahar S. A. (2009). Alpha-tocopherol and ginger are protective on Cyclophosphamide-induced gonadal toxicity in adult male albino rats. *Basic and Applied Pathology* 2009; 2: 21–29.
- Lee P.A. and Coughlin M.T. (2001). Fertility after Bilateral Cryptorchidism Evaluation by Paternity, Hormone, and Semen Data. *Horm Res* 2001; 55:28–32.
- Lutz Slomianka (2009). Blue Histology- Male Reproductive System. School of Anatomy and Human Biology - The University of Western Australia.
- Marklund S. and Marklund G. (1974). Involvement of the superoxide anion radical in the autoxidation of pyrogallol and a convenient assay for superoxide dismutase. *Eur J Biochem.* 47: 469-474.
- Mescher A.L. (2009). Junquiera's Basic Histology: Text and Atlas. 12th Ed. Pg- ISBN 978-0-07-160431-4; MHID 0-07-160431-6.
- Oyewopo AO, Saalu LC, Osinubi AA, Imosemi IO, Omotoso GO, Adefolaju GA. (2010). The attenuating effects of zinc on Propoxur-induced oxidative stress, impaired spermatogenesis and deranged steroidogenesis in Wistar rats. *Journal of Medicine and Medical Sciences*, Vol. 1(5) pp. 178-184. June 2010.
- Oyewopo O. A. and Togun V. A. (2005) Effect of temperature on motility and concentration on male Sprague Dawley rats epididymal spermatozoa. *Sci. Focus.* 10: 35-40.
- Rosa Vigueras-Villaseñor M., Idahue O., Oscar Gutierrez-Pérez, Margarita Chavez-Saldaña, Osvaldo C., Daniel S.M., and Julio Rojas-Castañeda C. (2011). Protective effect of α -tocopherol on damage to rat testes by experimental cryptorchidism. *Int J Exp Pathol.* 2011 Apr; 92(2): 131–139.
- Saalu, L.C., Oluyemi, K.A. and Omotuyi, I.O. (2014). Alpha-Tocopherol (vitamin E) attenuates the testicular toxicity associated with experimental cryptorchidism in rats. *African Journal of Anatomy* Vol. 1 (1), pp. 001 -005, January, 2014.
- Sedlak J. and Lindsay R.H. (1968). Estimation of total, protein-bound and non-protein sulfhydryl groups in tissues with Ellman's reagent. *Analytical Biochemistry*, 25: 192-205.
- Shikone T., Billig H. and Hsueh A.J. (1994). Experimentally induced cryptorchidism increases apoptosis in rat testis. *Biol Reprod.* 1994 Nov; 51(5):865-72.
- Thundathi J.C., Rajamanickam G.D., Kastelic J.P., Newton L.D. (2012). The effects of increased testicular temperature on testis-specific isoform of Na⁺/K⁺ -ATPase in sperm and its role in spermatogenesis and sperm function. *Reprod Domest Anim.* 2012 Aug; 47 Suppl 4:170-7.
- Traber M.G. and Kayden H.J. (1987). Tocopherol distribution and intracellular localization in human adipose tissue. *The American journal of clinical nutrition.*
- Wood H.M., Elder J.S. (2009). "Cryptorchidism and testicular cancer: separating fact from fiction". *The Journal of urology* 181 (2): 452–61.